

# Ocular motor nerve palsies: implications for diagnosis and mechanisms of repair

James A. Sharpe\*, Agnes M.F. Wong and Mohammad Fouladvand

*Division of Neurology and Department of Ophthalmology and Vision Sciences, University Health Network,  
University of Toronto, Toronto, Ontario, Canada*

**Abstract:** Measurements of the dynamics of the eyes in ocular motor nerve palsies may aid diagnosis, characterize peripheral and central palsies, and reveal adaptive properties of the brain. Saccadic and vestibulo-ocular reflex (VOR) functions of patients with peripheral and central sixth, and peripheral third and fourth nerve palsies were studied by three dimensional magnetic field search coil oculography. Combined third and fourth cranial nerve microvascular ischaemic palsy in diabetes mellitus produced low ratios of intorsion to adduction amplitudes. Presumed isolated third nerve palsy caused higher ratios of adduction to intorsion and violations of Listing's law. The VOR in third, fourth, and sixth nerve palsies reveals adaptive equilibration of the action of paretic agonist and their non-paretic antagonist muscles in violation of Hering's law during head motion. Saccadic speeds in the field of paretic agonists are repaired in chronic peripheral palsies despite limited ductions, but remain reduced in central palsies. Limited intorsion with third nerve palsy is attributed to concurrent fourth nerve ischaemia in the distribution of the inferolateral trunk of the intracavernous carotid artery. Adaptive repair of the VOR after ocular motor nerve palsies reduces asymmetric retinal image slip and binocular disparity, and repair of saccadic velocity drives both eyes rapidly and simultaneously into the paretic field of motion.

**Keywords:** ocular motor nerves; abducens nerve; trochlear nerve; oculomotor nerve; saccades; vestibulo-ocular reflex; adaptation; peripheral neuropathy; diabetes mellitus

## Introduction

Assessment of paralytic strabismus typically emphasizes static deviations rather than its effects on eye motion. Investigation of the effects of peripheral and central ocular motor nerve palsies on movement can reveal diagnostic features and identify adaptive and repair properties of the central and peripheral nervous systems.

Peripheral third (IIIrd; oculomotor) nerve palsy in diabetes mellitus has an ischaemic microvascular mechanism (Asbury et al., 1970; Weber et al., 1970). The IIIrd nerve palsy may be isolated or associated with involvement of the other cranial nerves (Lapresle and Lasjaunias, 1986). We report simultaneous palsy of the IIIrd and fourth (IVth; trochlear) nerves, propose an explanation of this distinctive combination, and employ three dimensional (3-D) oculography to characterize IVth nerve palsy when it is combined with IIIrd nerve palsy.

Effects of unilateral peripheral sixth (VIth; abducens), IIIrd, and IVth nerve palsies on the

---

\*Corresponding author. Tel.: + 416-603-5950;  
Fax: + 416-603-5596; E-mail: james.sharpe@uhn.on.ca

angular vestibulo-ocular reflex (VOR) reveal changes in the actions of antagonists to paretic muscles that implicate monocular adaptations to peripheral neuromuscular deficits.

The abducens is the only motor nerve with an ample course both within and outside the brain and it innervates only one muscle, the lateral rectus. VIth nerve palsy affords opportunity to compare recovery after central versus peripheral nerve damage by assessing the dynamics of abduction.

## Methods

Patients with unilateral IIIrd, IVth, or VIth nerve palsies were investigated by 3-D search coil oculography using 6 ft diameter field coils (CNC Engineering, Seattle, WA, USA). In each eye, the patient wore a dual-lead scleral coil annulus to detect horizontal, vertical, and torsional gaze positions (Skalar Instrumentation, Delft, Netherlands). Eye position data were filtered with a bandwidth of 0–90 Hz and digitized at 500 Hz.

Three diabetic patients with, pupil sparing, unilateral IIIrd nerve palsies were compared during attempted adduction or depression while fixation with the paretic eye with the normal eye occluded to determine the amplitude of saccades and any associated torsion.

The VOR in darkness and the visually enhanced VOR (VVOR) during fixation were tested with active head on body motion in yaw, pitch, and roll at frequencies of 0.5, 1.0, and 2.0 Hz at one point in the course of 21 patients with VIth nerve palsy (symptom duration ranged from 2 weeks to 96 months, mean duration: 16 months), 10 patients with IIIrd nerve palsies (symptom duration was 1 week to 50 months, mean duration: 18 months), and in 13 patients with IVth nerve palsies (duration 1 week to 132 months, mean duration: 35 months) and expressed as changes from normal subject values, rather than serial intra-subject changes. Any recovery towards normal values was not assessed and abnormalities are interpreted as deficits, or adaptation to those deficits (Wong and Sharpe,

2002; Wong et al., 2002a, b). Results were compared with recordings from 15 normal subjects.

Saccades were measured in 19 patients with unilateral VIth nerve palsy; 14 patients had idiopathic, presumed ischaemic, peripheral palsy, and normal MR or CT imaging. Symptom durations ranged from 3 weeks to 96 months, (mean duration: 21 months). Patients with diplopia of less than 1 month duration were classified as having *acute* palsy; all others were designated here as *chronic*. Five patients were tested acutely (within 1 month of symptom onset). Serial eye movement recordings were performed on these five patients with acute peripheral palsy, first at presentation and then at 2 months after symptom onset. Five of the 19 patients had central (fascicular) VIth palsies identified on MR imaging; two had cavernomas and three multiple sclerosis, involving the abducens nerve fascicle in the pons, but sparing its nucleus. Two of the five patients with central palsies were tested acutely (within 1 month of symptom onset). All measurements were performed for saccades to targets 10 degrees left and right of orbital midposition, within the range of limited duction caused by the palsy. Serial recordings were performed on those two patients with acute, central fascicular palsy, at presentation and at 2 months after symptom onset (Sharpe et al., 2005; Wong et al., 2006). Recordings from 10 normal adult subjects provided control data.

## Results

### *Combined IIIrd and IVth versus isolated IIIrd nerve palsies*

In a patient with IIIrd palsy attempted adduction, upward, and downward gaze, recordings showed little torsional movements of the right eye, during adduction or depression indicating simultaneous IIIrd and IVth nerve palsies. The ratio of maximum intorsion amplitude to maximums or adduction amplitude was 0.25 (SD 0.03,  $n=10$ ). Other patients with isolated IIIrd palsies showed intorsion of the palsied eye during attempted adduction and

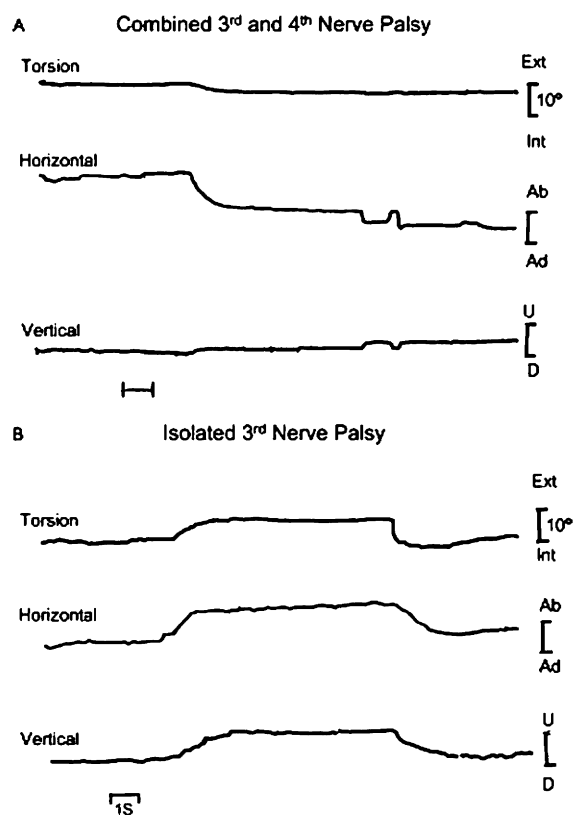


Fig. 1. A. Eye positions of a patient with combined diabetic right IIIrd and IVth nerve palsy has little torsional movement (top trace), during maximal adduction (Ad) saccade (middle trace). B. Recording of a patient with isolated diabetic right IIIrd nerve palsy shows intorsion (Int) (top trace) during adduction saccade (middle trace), indicating intact trochlear nerve and superior oblique muscle function. Slow extorsion (Ext) during abduction (Ab) saccade is explained by paresis of the inferior oblique muscle in comparison to faster intorsion generated by the intact superior oblique muscle. Vertical saccades are slowed upward (U) and downward (D) by paresis of the superior and inferior rectus muscles (bottom trace).

depression and had ratios of intorsion to adduction of 1.16 (SD 0.52) to 0.94 (SD 0.49) during adduction (Fig. 1) in violation of Listing's law.

### *The VOR in IIIrd, IVth, and VIth nerve palsies*

In VIth nerve palsy all 21 patients had decreased horizontal VOR gains in darkness in the paretic

eye in both abduction and adduction, but gains remained normal in the non-paretic eye in both directions. In light, horizontal VVOR gains were normal in both eyes in moderate and mild palsy. In severe palsy (with centrifugal abduction <50% of normal range) horizontal VVOR gains were low in the paretic eye in both directions, during viewing with either eye (Fig. 2), while those in the non-paretic eye were higher than normal when the paretic eye viewed.

Similarly, in IIIrd nerve palsy horizontal, vertical, and torsional VOR and VVOR gains of the paretic eye were decreased during abduction and adduction, elevation and depression, and extorsion and intorsion. In IVth nerve palsy horizontal, torsional, and vertical VOR gains of the paretic eye of the 13 patients were reduced symmetrically for abduction and adduction, for depression and elevation, and for intorsion and extorsion in darkness. In light, during paretic eye viewing, horizontal torsional VVOR gains remained low in directions of the paretic agonist and intact antagonists, but vertical and horizontal VVOR gains were normal. In both IIIrd and IVth nerve palsies VOR and VVOR gains in the non-paretic eye were normal for torsion and vertical and horizontal head motion. Neither eye showed any significant phase shift from zero in light or in darkness in any direction in IIIrd, IVth, or VIth nerve palsies.

### *Saccades in central versus peripheral VIth nerve palsies*

In acute state of peripheral ischaemic VIth nerve palsies, centrifugal abducting saccades in the paretic eye had reduced peak velocities (Fig. 3A) and longer durations for any given amplitude ( $p < 0.05$ ), as anticipated from weakness of the lateral rectus muscle. However, in the chronic state, centrifugal abducting saccadic peak velocities (Fig. 3A) and durations in the paretic eye were within the normal range in the nine chronic peripheral VIth palsies, despite persistent limited abduction. In the five patients with central (fascicular) VIth nerve palsy centrifugal abducting

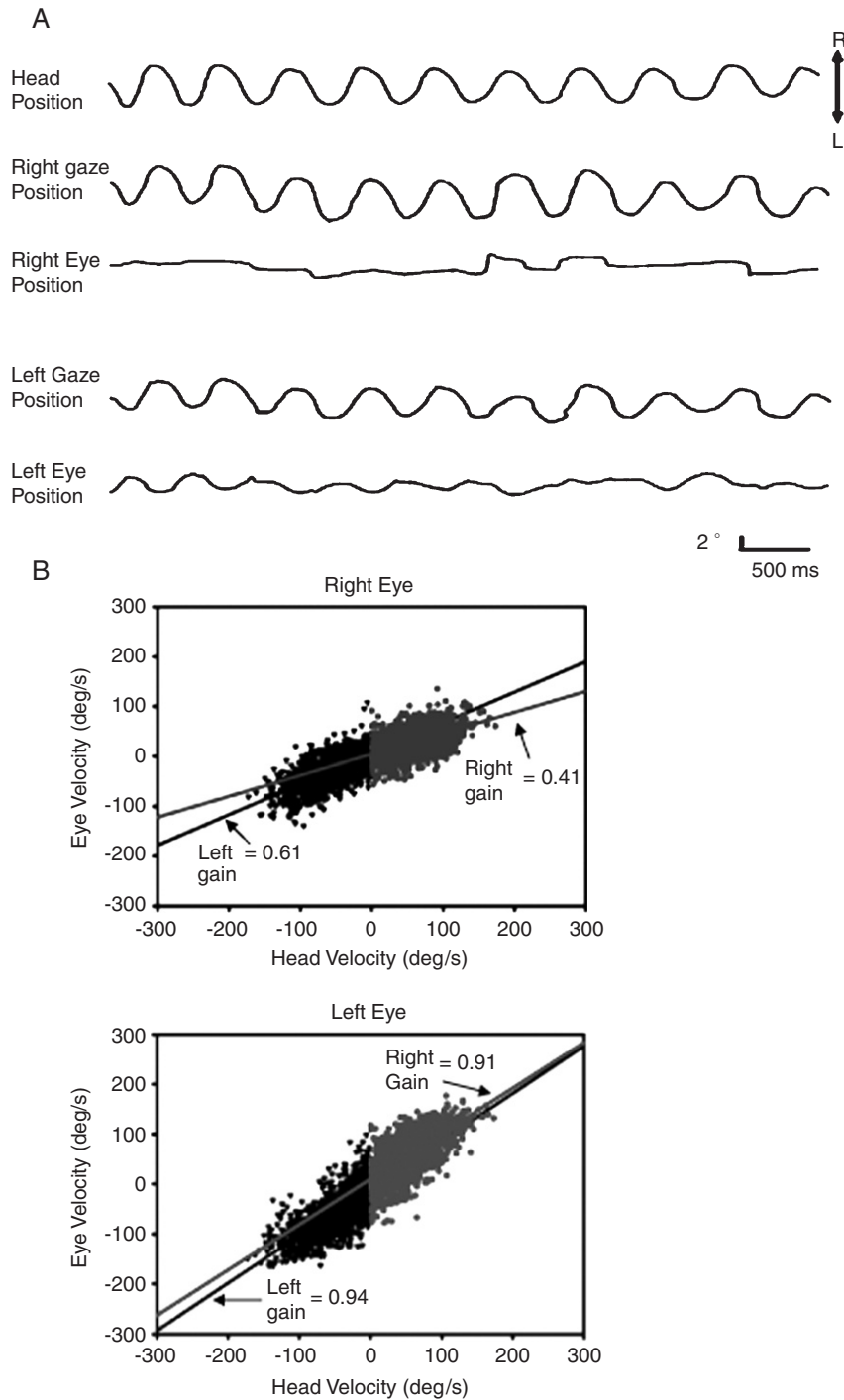


Fig. 2. A. Recording of head, eye, and gaze positions in darkness of a patient with a severe right sixth nerve palsy during horizontal head rotation at 2 Hz shows low amplitudes of eye motion to right and left (third trace). The non-paretic eye shows symmetrical higher horizontal amplitude VOR motion (bottom trace). Gaze is measured from coil on right eye (second trace) and left eye (fourth trace). R, rightward; L, leftward. B. VOR gains of right eye (top) and left eye (bottom) in a patient with a right sixth nerve palsy are shown by slopes of best fit lines of data points (dots), plotting head velocity against vestibular smooth eye movement velocity during head rotation at 2 Hz. In the parietic right eye both rightward (abducting) slope (gain 0.41) of and leftward (adducting) slope (gain 0.61) are reduced. For the non-paretic left eye adducting (rightward) VOR gain (0.91) and abducting (leftward) gain (0.94) are symmetrical.

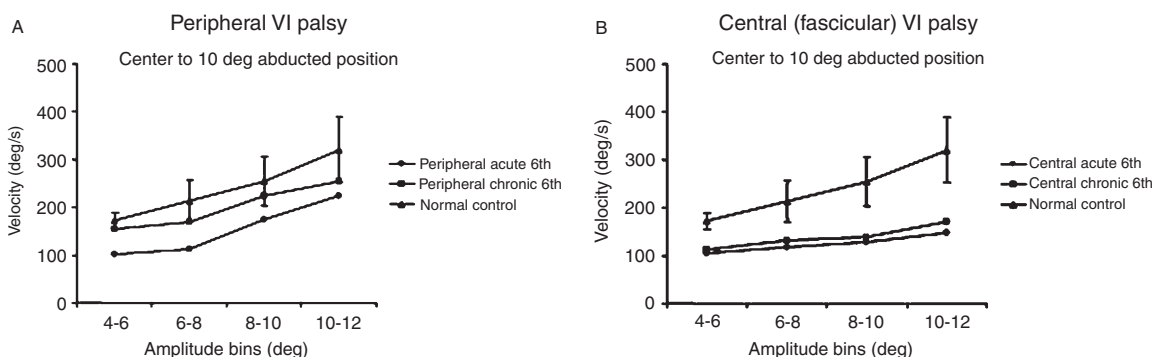


Fig. 3. Mean saccade peak velocities plotted against amplitude show reduced speed of centrifugal abducting saccades in both acute peripheral (A) and central (B) sixth nerve palsies. The paretic eye is used for viewing with the normal eye occluded. In chronic peripheral palsies speed became normal (A) but in chronic central palsies (B) it remained subnormal. Error bars indicate 1 standard deviation from normal group mean.

saccades in the paretic eye had subnormal peak velocities and long durations for any given amplitude, both in the acute and chronic states (Fig. 3B) ( $p < 0.05$ ).

## Discussion

### *Ischaemic ocular motor mononeuropathy versus polyneuropathy*

Palsies of the IIIrd cranial nerve from diabetes mellitus or idiopathic presumed ischaemic origin are usually isolated but may be associated with other cranial neuropathies (Annabi et al., 1979; Lapresle and Lasjaunias, 1986). We detected simultaneous IIIrd and IVth nerve palsy in diabetes by 3-D oculography. Their vascular supply to the IIIrd and IVth nerves in their intracavernous region is the inferolateral trunk (ILT), arising from the internal carotid artery. The superior or tentorial branch of the ILT supplies both the IIIrd and IVth nerves, but not other nerves (Lasjaunias et al., 1977; Krisht et al., 1994). Clinical examination of patients with pupil-sparing IIIrd nerve palsy may reveal intorsion during attempted adduction or depression, but the recording (Fig. 1) confirmed the presence of torsion and hence spared IVth nerve function in those patients.

During attempted elevation or depression of the eye innervation of the inferior oblique muscle by

the IIIrd nerve must be balanced by innervation of the IVth nerve to restrain torsion and thereby preserve Listing's law (Ferman et al., 1987). In the presence of paresis of the inferior oblique muscle caused by the IIIrd nerve palsy, the unopposed action of the superior oblique muscle is evident, causing intorsion in violation of Listing's law (Fig. 1B), but in the presence of a combined IVth nerve palsy a restraint on torsion is evident (Fig. 1A). After isolated IVth nerve transection in monkeys Listing's law is largely preserved (Tian et al., 2007). Since both elevation and depression are variably paralysed in IIIrd nerve palsy, but adduction from an abducted position to at least the orbital midposition is preserved, the ratio of intorsion to adduction may be a useful quantitative parameter of assessing paresis or sparing of the IVth nerve, and contribute to localizing the IIIrd nerve palsy to its intracavernous segment when the IVth nerve is also paretic.

### *Adaptations and deficits in the vestibulo-ocular reflex*

Angular VOR gains after unilateral ocular motor nerve palsies are reduced during movement in the directions of actions of paretic muscles as anticipated from their palsy. However gains are also reduced in the fields of actions of their intact antagonist muscles after IIIrd, IVth, or VIth nerve

palsies (Wong and Sharpe, 2002; Wong et al., 2002a, b). VOR gains in the non-paretic eye remain normal, implicating a selective adjustment of the paretic eye, specifically to the antagonists of paretic muscles. In light, visual input increases gain of the paretic eye in the motion fields of both paretic agonist muscles and their antagonist muscles, when the paretic eye is used for fixation, while VVOR gains in the non-paretic eye remain normal; this provides further evidence of selective adaptation of innervation to the paretic eye. Torsional dynamic VOR and VVOR gains of the paretic eye are reduced for both extorsion and intorsion in IIIrd and IVth nerve palsies (Wong and Sharpe, 2002; Wong et al., 2002a; Sharpe et al., 2003). Motion of the eyes after nerve palsies exemplifies monocular adaptation of the VOR in three dimensions.

After severe VIth nerve palsy, when the centrifugal range of abduction was limited to less than 50% of the full range of normal, viewing with the paretic eye increases its abducting and adducting horizontal VVOR gains above VOR gains in darkness but they remain below normal levels in the paretic eye, whereas VVOR gains in the covered non-paretic eye increase to values above unity. In terms adapted from strabismology, the gains measured during fixation with the non-paretic (normal) eye reveal the “primary” VVOR, while gains measured during fixation with the paretic eye reveal the “secondary” VVOR in the non-paretic eye. Elevation of VVOR gain in the non-paretic occluded eye to values above the ideal value of 1.0 during distant fixation with the paretic eye is attributed to increased innervation of yoked muscles of the non-paretic eye, in accordance with Hering’s law (see below). However, in mild and moderate palsy vision enhances the VOR in the paretic eye but causes no change in the non-paretic eye, indicating a monocular readjustment of innervation selectively to the paretic eye.

If the VOR gain in the direction of action of antagonists of paretic muscles did not decrease the VOR would be asymmetric in the paretic eye, rotating it further in the direction of action of the intact antagonist with each head rotation, and resulting in increasing position disparity between the two eyes and more diplopia. In the case of a

left lateral rectus weakness from a left VIth nerve palsy (for example), any adaptive reduction in innervation to the left medial rectus muscle would be accompanied by reduced innervation to the right lateral rectus muscle, in accordance with Hering’s (1868) proposal or law that the brain controls binocular movements conjugately by simultaneous innervation of yoked pairs of muscles in each eye. However the gain in the non-paretic eye remained normal in both adduction and abduction. Monocular adaptation of VOR and saccadic gain to weakening ocular muscles has been detected in monkeys (Snow et al., 1985; Viirre et al., 1988), but selective effects on paretic muscles or their intact antagonists had not been identified. Selective reduction of VOR gains during action of the antagonist of the paretic muscle by reducing its innervation is apparently the strategy that the brain uses to balance the VOR (Wong and Sharpe, 2002; Wong et al., 2002a, b; Sharpe et al., 2003).

Changes from normal orbital plant mechanics might contribute to the decreased VOR gains in the direction of the antagonists to paretic muscles. The relative contribution of agonist contraction and antagonist relaxation varies with orbital position (Collins, 1975), and it may be altered when one muscle of an agonist–antagonist pair is palsied. Contracture is characterized by muscle shortening and stiffening as a result of decreased number of sarcomeres (Scott, 1994). If the reduction of VOR gains in both directions were due to changes in extraocular muscle mechanics, one would expect VOR gains in the paretic eye to be subnormal during rotation in light (the VVOR) as well as in darkness. However, the results indicate that while VOR gains were decreased, VVOR gains could increase to normal values in light (Sharpe et al., 2003). The results provide evidence that decrease VOR gains in the antagonist of paretic muscles, and equilibration of gains in the directions of paretic agonists and their intact antagonists is not the result of changes in mechanical properties of the orbital plant, but due to a functional, central adaptation to the palsy. Altered proprioceptive inflow (Lewis et al., 1994; Gentle and Ruskell, 1997) from a shortened (slack) antagonist or a palsied muscle might

participate in the monocular adaptations after peripheral nerve palsies. Binocular disparity of retinal images that increases during head motion and asymmetry of retinal image slip when the VOR is imbalanced by palsy of a muscle appears to be the visual drive for monocular adaptation to reduce image slip, and diplopia.

### ***Recovery of saccadic velocity in VIth nerve palsy***

Patients with *central* palsy, both acute and chronic, had slow abducting saccades but in patients with *peripheral* palsy, abducting saccadic speed became normal in the face of persistent esotropia when tested 2 months after the onset of diplopia, (Sharpe et al., 2005; Wong et al., 2006). Recovery of abducting saccadic velocity in the paretic after peripheral neuropathy may be due to partial regeneration of axons or myelin of the peripheral nerve. The partially recovered peripheral nerve allows the transmission of high firing rates so that saccades are of normal peak velocity. In contrast, tonic signals are impaired resulting in abnormal position (i.e., esotropia) and the limited abduction of the paretic eye, evident in patients in both the acute (<1 month) and chronic states. Disparity between the repair of saccade speed and the persistence of defective ranges of abduction may be due to the selective nature of the nerve fibres damaged or the tempo of their regeneration and remyelination. Large motoneurons within the abducens nucleus innervate singly innervated, twitch muscle fibres, whereas smaller motoneurons around its periphery innervate multiply innervated, non-twitch muscle fibres (Buttner-Ennever et al., 2001, 2003). Normal speed but restricted duction might be explained by either predominant damage to nerve fibres from non-twitch nerve fibres motoneurons just outside the abducens nucleus, or by better repair of nerve fibres from twitch motoneurons within the nucleus. In contrast the absence of recovery saccade speed and range in patients with central palsy indicates limited regeneration of damaged axons and myelin in the glial environment of the brain (Fenrich and Gordon, 2004).

Alternatively, recovery may represent a monocular readjustment of innervation selectively to the

paretic eye. A pre-nuclear substrate for possible monocular adjustments of saccade speed in response to peripheral nerve palsy is found in pre-saccadic burst neurons of the caudal paramedian pontine reticular formation (PPRF) which encode monocular movements of either abduction or adduction (Zhou and King, 1998). This organization is contrary to Hering's law. Whether the recovery of saccadic speed in chronic peripheral palsy indicates partial axonal regeneration, remyelination, or monocular adaptation, or all three mechanisms, it allows both eyes to reach targets in the paretic hemifield of motion rapidly and simultaneously.

### **Acknowledgement**

Supported by Canadian Institutes of Health Research (CIHR) Grants MT 15362 and ME 5504.

### **References**

- Annabi, A., Lasjaunias, P. and Lapresle, J. (1979) Paralysis of the 3d cranial nerves in diabetes and common oculomotor vascularization. *J. Neurol. Sci.*, 41: 359–367.
- Asbury, A.K., Aldredge, H., Hershberg, R. and Fisher, C.M. (1970) Oculomotor palsy in diabetes mellitus: a clinicopathological study. *Brain*, 93: 555–566.
- Buttner-Ennever, J.A., Eberhorn, A. and Horn, A.K. (2003) Motor and sensory innervation of extraocular eye muscles. *Ann. N.Y. Acad. Sci.*, 1004: 40–49.
- Buttner-Ennever, J.A., Horn, A.K.E., Scherberger, H. and D'Ascanio, P. (2001) Motoneurons of twitch and nontwitch extraocular muscle fibers in the abducens, trochlear, and oculomotor nuclei of monkeys. *J. Comp. Neurol.*, 438: 318–335.
- Collins, C.C. (1975) The human oculomotor control system. In: Lennerstrand G. and Bach-y-Rita P. (Eds.), *Basic Mechanisms of Ocular Motility and Their Clinical Implications*. Pergamon Press, Inc., New York, pp. 145–180.
- Fenrich, K. and Gordon, T. (2004) Axonal regeneration in the peripheral and central nervous systems: current issues and advances. *Can. J. Neurol. Sci.*, 31: 142–156.
- Ferman, L., Collewyn, H. and Berg, A.V. (1987) A direct test of Listing's law-II: human ocular torsion measured under dynamic conditions. *Vision Res.*, 27: 939–951.
- Gentle, A. and Ruskell, G. (1997) Pathway of the primary afferent nerve fibers serving proprioception in monkey extraocular muscles. *Ophthalmic Physiol. Opt.*, 17: 225–231.
- Hering, E. (1868) *Die Lehre vom binokularen Sehen*. Wilhelm Englemann, Leipzig, Germany.

- Krisht, A., Barnett, D.W., Barrow, D.L. and Bonner, G. (1994) The blood supply of the intracavernous cranial nerves: an anatomic study. *Neurosurgery*, 34: 275–279, discussion 279.
- Lapresle, J. and Lasjaunias, P. (1986) Cranial nerve ischaemic arterial syndromes: a review. *Brain*, 109: 207–216.
- Lasjaunias, P., Moret, J. and Mink, J. (1977) The anatomy of the inferolateral trunk (ILT) of the internal carotid artery. *Neuroradiology*, 13: 215–220.
- Lewis, R.F., Zee, D.S., Gaymard, B.M. and Guthrie, B.L. (1994) Extraocular muscle proprioception functions in the control of ocular alignment and eye movement conjugacy. *J. Neurophysiol.*, 72: 1028–1031.
- Scott, A.B. (1994) Change of eye muscle sarcomeres according to eye position. *J. Pediatr. Ophthalmol. Strab.*, 31: 85–88.
- Sharpe, J.A., McReelis, K. and Wong, A.M. (2005) Recovery of peripheral versus central nerves identified by saccadic velocity after abducens neuropathy. *Ann. N.Y. Acad. Sci.*, 1039: 417–429.
- Sharpe, J.A., Tweed, D. and Wong, A.M. (2003) Adaptations and deficits in the vestibulo-ocular reflex after peripheral ocular motor palsies. *Ann. N.Y. Acad. Sci.*, 1004: 111–121.
- Snow, R., Hore, J. and Vilis, T. (1985) Adaptation of saccadic and vestibulo-ocular systems after extraocular muscle tenectomy. *Invest. Ophthalmol. Vis. Sci.*, 26: 924–931.
- Tian, J., Shan, X., Zee, D.S., Ying, H., Tamargo, R.J., Quaia, C., Optican, L.M. and Walker, M.F. (2007) Acute superior oblique palsy in monkeys: III. Relationship to Listing's law. *Invest. Ophthalmol. Vis. Sci.*, 48: 2621–2625.
- Viirre, E., Cadera, W. and Vilis, T. (1988) Monocular adaptation of the saccadic system and vestibulo-ocular reflex. *Invest. Ophthalmol. Vis. Sci.*, 29: 1339–1347.
- Weber, R.B., Daroff, R.B. and Mackey, E.A. (1970) Pathology of oculomotor nerve palsy in diabetics. *Neurology*, 20: 835–838.
- Wong, A.M., McReelis, K. and Sharpe, J.A. (2006) Saccade dynamics in peripheral vs. central sixth nerve palsies. *Neurology*, 66: 1390–1398.
- Wong, A.M.F. and Sharpe, J.A. (2002) Adaptations and deficits in the vestibulo-ocular reflex after third nerve palsy. *Arch. Ophthalmol.*, 120: 360–368.
- Wong, A.M.F., Sharpe, J.A. and Tweed, D. (2002a) The vestibulo-ocular reflex in fourth nerve palsy: deficits and adaptations. *Vision Res.*, 42: 2205–2218.
- Wong, A.M.F., Tweed, D. and Sharpe, J.A. (2002b) Adaptations and deficits in the vestibulo-ocular reflex after sixth nerve palsy. *Invest. Ophthalmol. Vis. Sci.*, 43: 99–111.
- Zhou, W. and King, W.M. (1998) Premotor commands encode monocular eye movements. *Nature*, 393: 692–695.